

**Case Study: the Efficacy of Equine Cymatherapy
Bioresonance on a Superficial Digital Flexor Tendon
Core Lesion of a Thoroughbred Racehorse Colt**

*Keith Cooper
Elizabeth Colorio
Penny Jenks*

Case Study: the Efficacy of Equine Cymatherapy Bioresonance on a Superficial Digital Flexor Tendon Core Lesion of a Thoroughbred Racehorse Colt

Keith Cooper, Elizabeth Colorio, Penny Jenks

Initial Clinical Evaluation

Rarely Found, a Thoroughbred racehorse colt, was shipped to Penny Jenks, in Louisiana, as a referral from the state of Florida.

Rarely Found was first seen on 4-09-04 by Keith Cooper DVM, for a comprehensive clinical examination that included ultrasonographic imaging. Rarely Found initially presented with a clinical picture of lameness Grade 3.5 out of 5 of the left front limb for one week's duration before diagnosis and treatment. Lameness is graded on a scale of Grade 1 (least lame) to Grade 5 (most lame) in horses.

Rarely Found's initial clinical presentation on examination was pain to flexion and palpation of the digital flexor tendon area in about the middle, being, Zone 2. There was well defined, visible swelling as well as heat to the tendon area and edema in the tendon sheath area on palpation. The lesion was positively confirmed by ultrasonographic imaging on the day of the first comprehensive clinical examination and was diagnosed by Keith Cooper DVM as a 25 to 30% core lesion of the superficial digital flexor tendon (SDFT). The lesion was in the Zone 2 A and 2 B area. This core lesion was very concise without evidence of tendon damage outside of the core of the SDFT lesion area.

Rehabilitation: Physical Exercise Program

At this time, this colt's program of physical activity was confined to stall rest with hand walk for only about 5 minutes for the first 30 days.

Initial Treatment

Standard veterinary ancillary treatments included hydrotherapy and icing daily. Standard veterinary inflammation prophylaxis consisted of one injection of hyaluronic acid into the core lesion and tendon sheath.

The primary treatment of choice was a protocol of Equine Cymatherapy Bioresonance that consisted of applications of bioresonance to the tendon area as well as to acupuncture points and acupuncture meridians.

The initial primary bioresonance treatment was administered on 4-09-04 by Penny Jenks as directed by Dr. Cooper to the acupuncture meridians as follows: Small Intestine, Heart, Pericardium, Liver and the Gallbladder meridians.

The bioresonance treatments to the acupuncture points were further broken down into 2 segments. The first treatment segment was a Ting Point treatment schedule. The Ting Points are located around the coronary band of the feet. The Ting Points treated on the front feet were; Small Intestine 1, Large Intestine 1, Pericardium 9 and Heart 9. The Ting Points treated on the rear feet were; Liver 1 and Gallbladder 44.

The second treatment segment consisted of local points around the tendon area on the effected limb and included distal points to facilitate energy flow, enhance circulation and stimulate the healing process to facilitate the rapid rehabilitative process clearly demonstrated in this case study.

The local acupuncture points treated with Cymatherapy Bioresonance were: Small Intestine 1, 3, 4 and 5; Large Intestine 1, 2, 3, 4, 10 and 11; as well as Lung 10.

The distal points treated with bioresonance were: Small Intestine 16, Triple Heater 13, Large Intestine 16, and Gallbladder 34 on the rear limb. The Bladder Meridian such as Bladder 14, 15, 18, 19 and 27 were also used.

Continuing Treatment Protocol

The acupuncture point treatments administered by Penny Jenks consisted of the Cymatherapy Bioresonance commutation for Acupuncture Block Removal to the acupuncture points as stated in the initial treatment.

Cymatherapy Bioresonance commutations administered to the SDFT core lesion itself, for 10 minutes in duration each, were: Flexor Tendon, Adhesions Alternate, Connective Tissue, Tissue Damage, and Circulation.

Treatment Frequency Schedule of Equine Cymatherapy Bioresonance

- Five times per week for the first 2 weeks
- Three times per week for 60 days
- Once per week thereafter

Primary Diagnostic Ultrasonographic Images 4-09-04

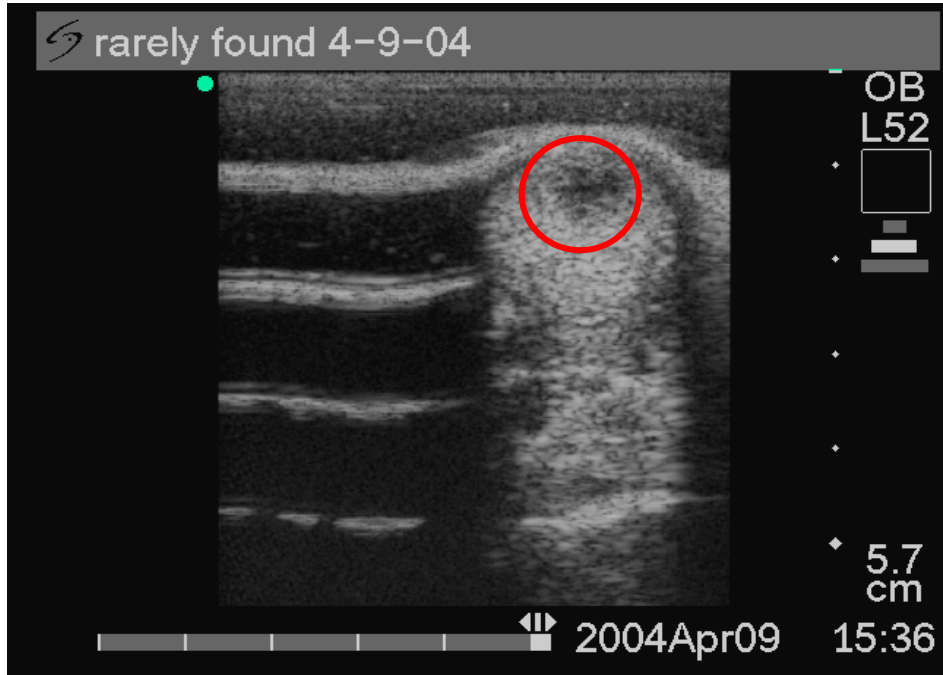


Image 1:1. Short axis ultrasonography of the SDFT 4-09-04

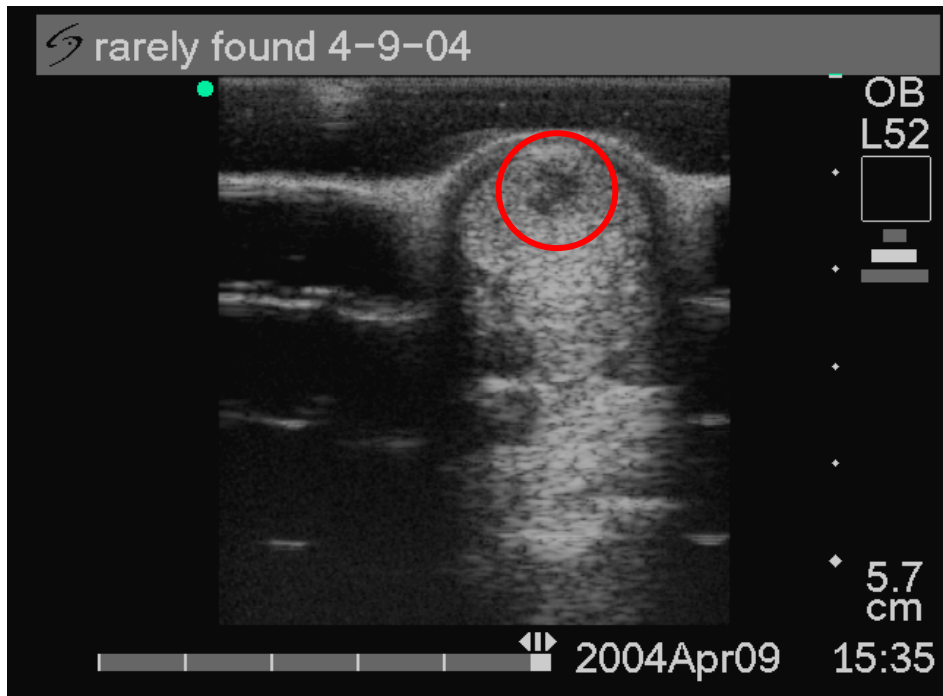


Image 2:2. Short axis ultrasonography of the SDFT 4-09-04

Ultrasound scan images during this primary clinical evaluation showed a very concise 25 to 30% core lesion of the superficial digital flexor tendon (SDFT).

First Follow-up Ultrasonographic Image and Clinical Evaluation 4-20-04

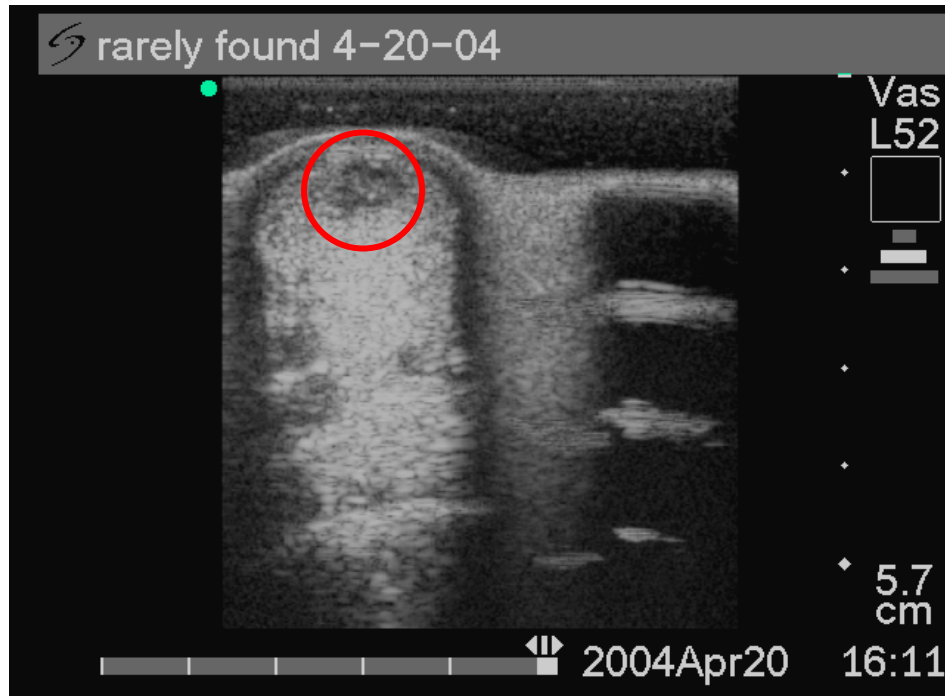


Image 1:3. Short axis ultrasonography of the SDFT 4-20-04

Clinical Evaluation

The first follow-up Ultrasound scan showed a 50% improvement in the SDFT core lesion size, with tendon cell density, fibrin deposition and collagen fibril formation as a clear indication of the hypoechogenic healing of this SDFT tendon lesion.

Clinically, there was a decrease in lameness from a Grade 3.5 to Grade 2 of 5. There was decreased sensitivity to flexion and palpation of the flexor tendon in the left front limb. There was also a marked decrease in swelling and no more heat felt on palpation to the tendon area or the limb.

Treatment Protocol

At this time daily treatments consisted of hydrotherapy with cold hose treatment and Cymatherapy Bioresonance to the acupuncture points already described.

Rehabilitation: Physical Exercise Program

Hand walking was increased to 10 minutes per day for the next 30 days.

Second Follow-up Ultrasonographic Images and Clinical Evaluation 5-09-04

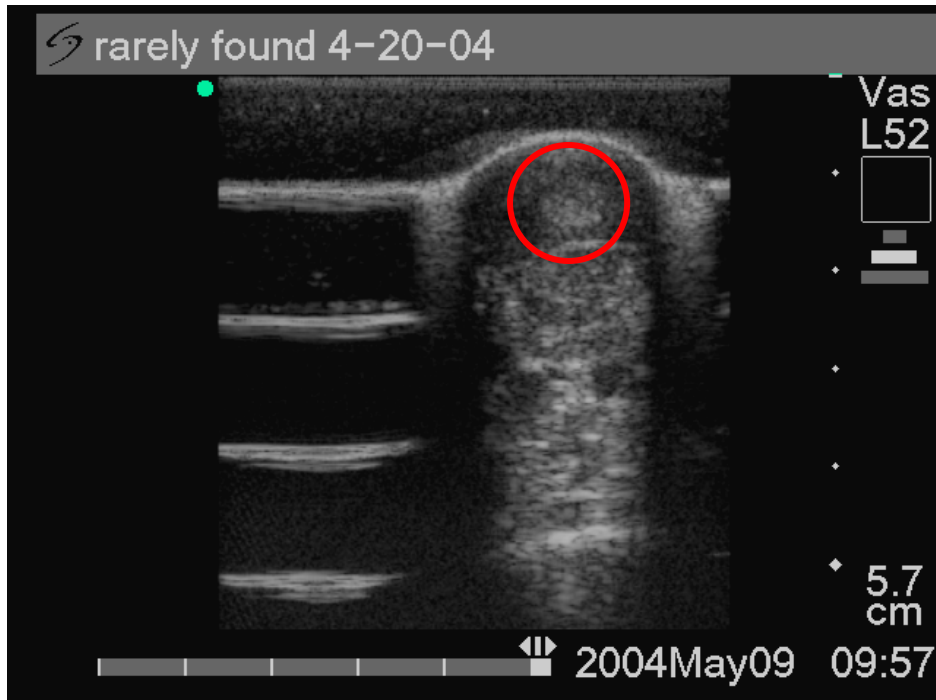


Image 1:4. Short axis ultrasonography of the SDFT 5-09-04

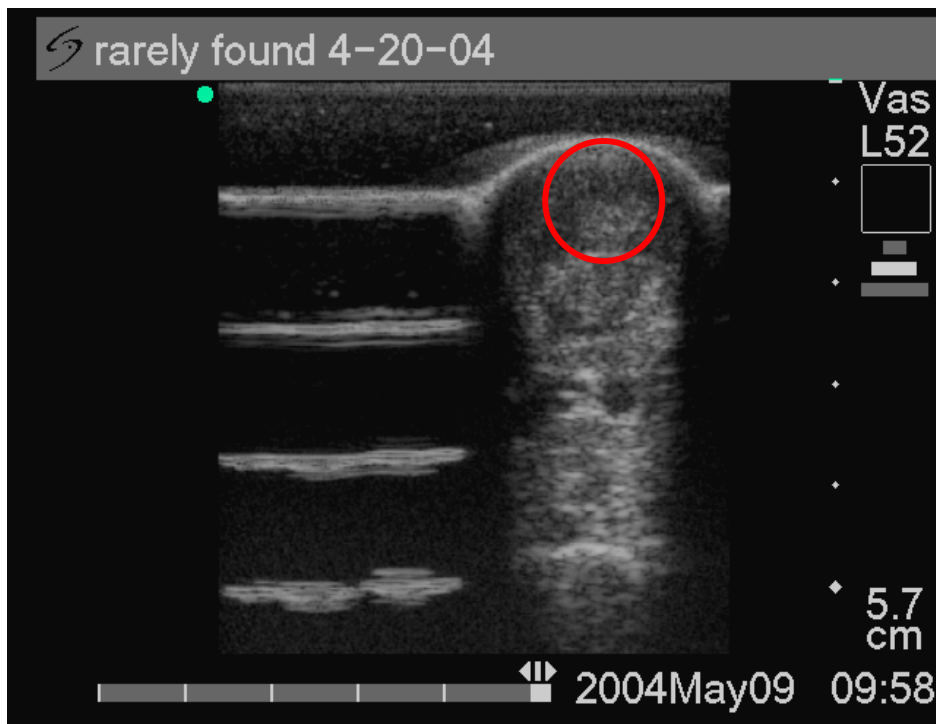


Image 2:5. Short axis ultrasonography of the SDFT 5-09-04

Clinical Evaluation

Ultrasound scan imaging showed a transition to a more uniform echogenicity with a complete reduction of the SDFT core lesion to a well defined tendon cell, fibrin and collagen filled area indicative of an accelerated healing process.

At this time clinical signs showed no lameness at the walk. There was no pain elicited during flexion or palpation. There was no visible swelling or heat felt during palpation.

Treatment Protocol

Cymatherapy Bioresonance treatments were continued as per schedule by Penny Jenks.

Rehabilitation: Physical Exercise Program

Hand walking was increased to 30-45 minutes per day. A light jog was also introduced into the rehabilitation program at this time. This stage of the rehabilitation program was followed for 21 days.

Third Follow-up Ultrasonographic Images 5-22-04

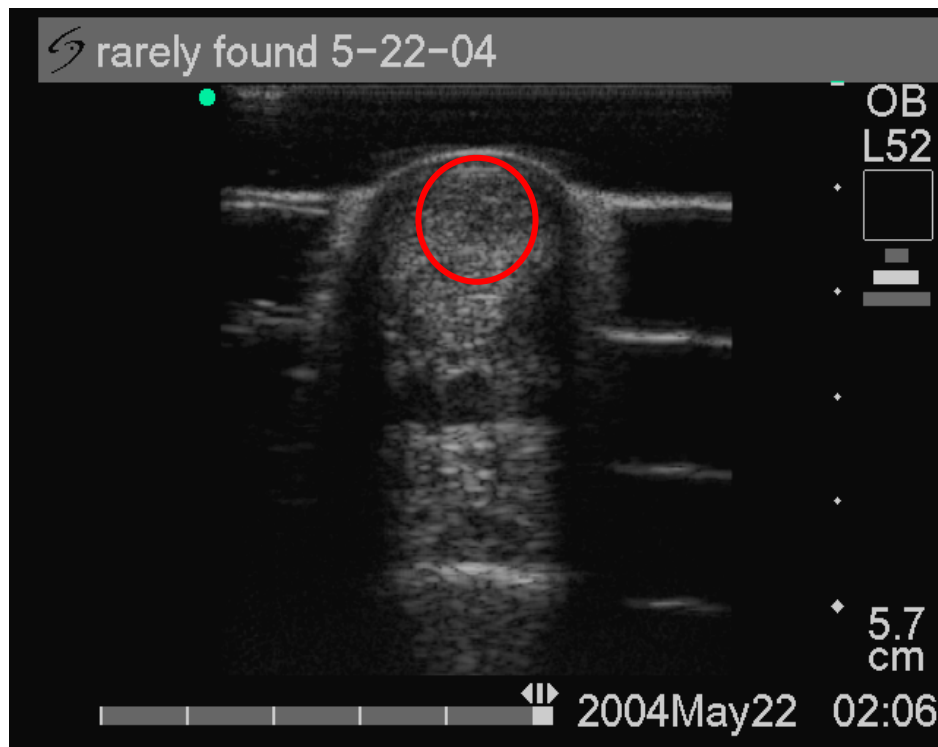


Image 1:6. Short axis ultrasonography of the SDFT 5-22-04

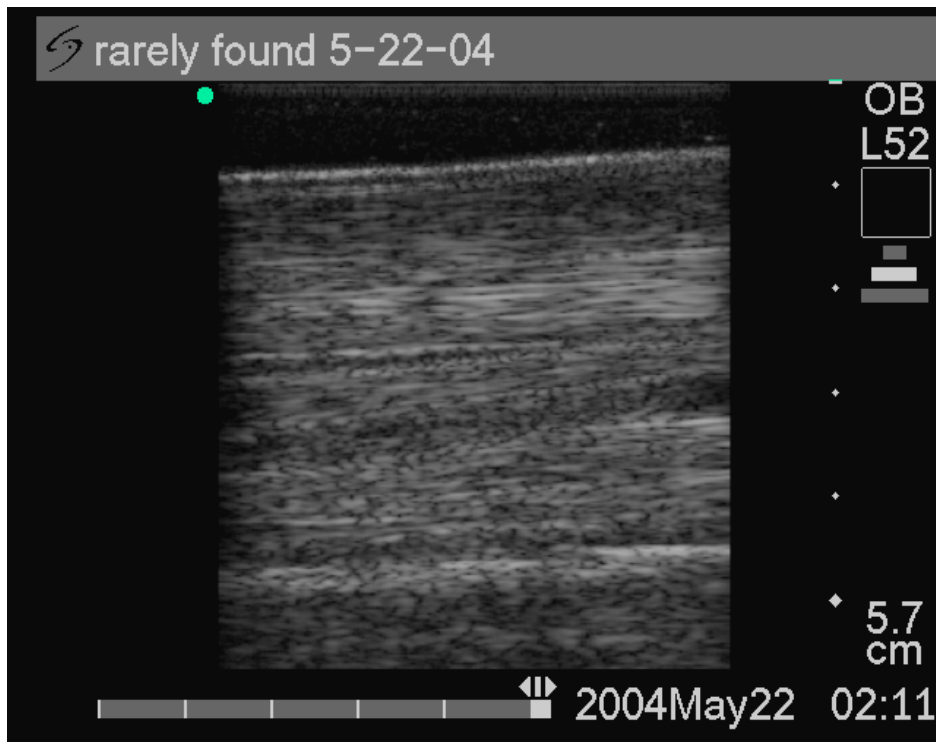


Image 2:7. Long axis ultrasonography of the SDFT 5-22-04

Clinical Evaluation

Image 1:6. Ultrasound scan showed a uniform and normal echogenicity with a complete reduction of the SDFT core lesion to a well defined tendon cell regeneration area with no evidence of a prior SDFT lesion.

Image 2:7. Ultrasound scan showed proper tendon cell and collagen fiber alignment with no further evidence of a prior SDFT core lesion.

At this time clinical signs showed no lameness at the jog or gallop. There was no pain elicited during flexion or palpation. There was no visible swelling or heat felt during palpation even after the increase in physical activity in the jog or gallop. There is no more evidence of lameness to date.

Treatment Protocol

Cymotherapy Bioresonance treatments were continued once per week.

Rehabilitation: Physical Exercise Program

Training was increased to one to 1.5 miles of jogging, every day, in Rarely Found's rehabilitation program at this time.

Discussion

The prognosis for return to use following injury to the SDFT in athletic horses has historically been graded fair to poor. According to the literature, the healing process can take from 6 to 24 months to occur and usually terminates with further evidence of disruption of normal fiber alignment and variable loss of echogenicity at the endpoint of study per follow-up ultrasonography.

Continued evidence of disruption of normal fiber alignment and variable loss of echogenicity are usually a result of adhesions and scar tissue that occur during the course of the healing process of an injured tendon. Any disruption, malalignment or change from the normal tendon cell alignment or consistency does predispose the horse to future reinjury.

The high cost in veterinary diagnostics, care, treatment and maintenance, as well as the loss in value of the athletic horse is difficult to recuperate by the horse owner rendering the promising horse athlete a very high cost to maintain without gainful return. The high morbidity rate in the tendon injured horse, coupled with the continued threat of reinjury, translates into a substantial financial loss to the horse owner over time.

Conclusions

In this exemplary case study, we have found a rapid rate of tendon healing as well as tendon healing with the ultrasonographic evidence of the return to normal and homogeneous tendon cell integrity as proven by the uniform and normal echogenicity.

The duration of healing time, as evidenced by ultrasonography, as well as the clinical signs of healing and rapid return to function was 43 days; from the first diagnostic ultrasound scan on 4-09-04 to the last ultrasound scan on 5-22-04 to date.

This clearly shows that Equine Cymotherapy Bioresonance treatments have surpassed any standard veterinary treatment of the SDFT injured horse by approximately 5 to 22.5 months ahead of any known standard treatments provided in the literature.

The high quality of the homogeneous, healed, tendon tissue, per ultrasonographic evidence, translated into a low to null continued morbidity or threat of reinjury.

The cost savings in veterinary diagnostics, care, treatment and maintenance over time, as well as the preservation in value of this athletic horse will further insure this horse owner a gainful return on their substantial financial investment.